

**Aggressive Myofibroma of Gingiva: A Case Report****Sobhana CR, Suresh Babu, Saurabh Kumar Rawat, Suryakant Yadav**

Department of Oral and Maxillofacial Surgery, Government Dental College, Thiruvananthapuram, Kerala, India

**Address for Correspondence:**

Dr. Saurabh Kumar Rawat, Department of Oral and Maxillofacial Surgery, Government Dental College, Thiruvananthapuram, Kerala, India.

**ABSTRACT:**

Myofibroma is an uncommon spindle cell neoplasm of rare incidence in oral cavity. Typically, this lesion is seen in neonates and infants with few cases reported in adults. In the oral cavity, myofibroma occurs within the submucosal or intramuscular tissue and has a predilection for the tongue, buccal mucosa and lips. Microscopically, a typical biphasic pattern can be observed. Misdiagnosis includes benign and malignant spindle cell lesions of nerve tissue or smooth muscle origin, such as neurofibroma, leiomyoma and sarcomas. Thus, immunohistochemical staining is a useful tool to identify the nature of neoplastic cells and to reach an accurate diagnosis. Here is a case of this rare benign tumor of gingiva in a child of one and a half year of age. Surgical excision of the lesion was done under general anaesthesia. Histopathologic and immunohistochemical examination suggested the diagnosis of myofibroma.

**Keywords:** Myofibroma, Spindle cells, Immunohistochemistry.**INTRODUCTION**

Myofibroma is a rare, benign mesenchymal tumor, most of which develop in infancy or before the age of 2 years. It was first described by Stout<sup>1</sup> in 1954 as Congenital Generalized Fibromatosis and renamed as Infantile Myofibromatosis by Chung et al. in 1981. According to Chung et al., about one-third of all myofibromas occur in head and neck, with few cases reported in oral soft tissues.<sup>2</sup>

Intraoral myofibromas usually are firm and painless masses, well circumscribed and relatively rare.<sup>3</sup> In 1989, a solitary case of this tumor was delineated by Smith et al. and was termed "Myofibroma". Afterwards, the terms "Myofibromatosis" and "Myofibroma" were adopted by WHO. Myofibroma involves predominantly the head and neck region (36%) or the trunk; however cases affecting the oral cavity are rare and present with a wide differential diagnosis.<sup>4</sup> Myofibroma presents as a single swelling when it occurs on the gingiva, and more common lesions such as Fibrouseplulis, Pyogenic granuloma and Peripheralodontogenic fibroma, myofibroma are usually considered in the differential

diagnosis. However, it is benign and is usually treated by complete surgical excision with excellent prognosis.

**CASE REPORT**

A one and a half year old male child presented to our department with a painless swelling in his upper gums noted 4 months back. Mother gives history of trauma to upper front teeth due to fall 5 months back. Following trauma, one tooth became discoloured and a small swelling appeared in the gums above the tooth after a month. Pulpectomy of maxillary right deciduous central incisor was done and lesion was excised under general anesthesia at another hospital. HPR suggested fibrous hyperplasia. Slide was reviewed in REGIONAL CANCER CENTRE, TRIVANDRUM which suggested spindle cell neoplasm—a possibility of myofibroma. About one and half month later, growth reappeared and kept on increasing in size and became about three times of its previous size at the time they reported to our department. There is no history of such a growth prior to this.

Medical history of the patient was noncontributory.

On examination, a 2.5x1.5cm sessile, pinkish, multilobular growth was seen in the gingiva above 51 (temporarily filled access opening) and 52. (Figure 1) Growth was firm and nontender on palpation. 51 was palatally displaced. There was no associated dental mobility and 51 was nonvital. IOPA X-ray revealed RCT treated 51. Based on history and previous histopathological report (RCC), diagnosis of myofibroma was made. Lesion was excised along with 51 and 52 under general anaesthesia. (Figure 3, Figure 4)

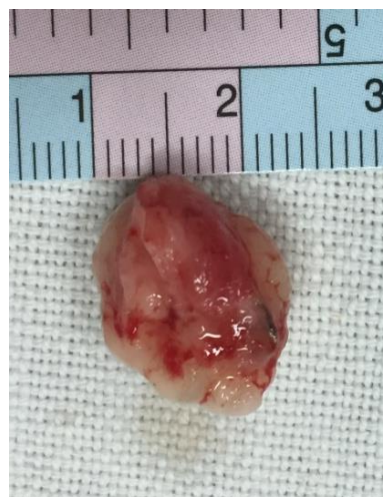

Figure 4: Excised specimen

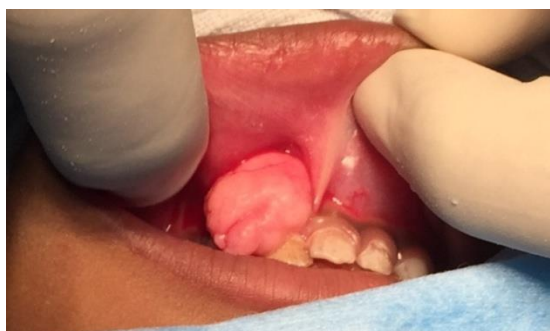

Figure 1: Preoperative findings Swelling in relation to 51 and 52

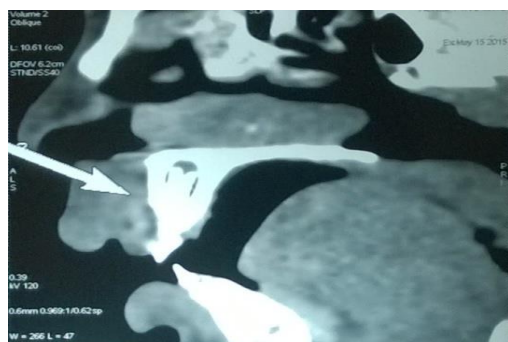


Figure 2: CT-scan maxilla

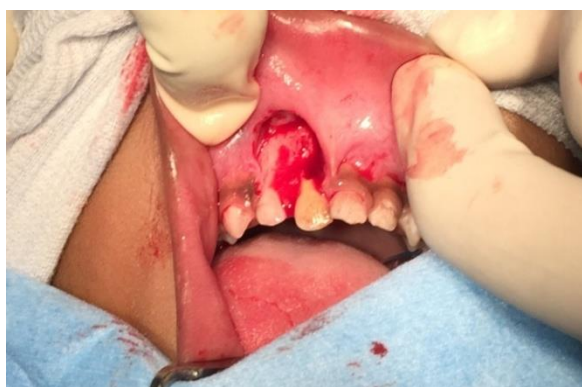

Figure 3: Intraoperative: Excision of the growth

Histopathological examination suggested-“parakeratinized stratified squamous epithelium with thin and elongated rete ridges exhibiting pseudoepitheliomatous hyperplasia. Proliferating connective tissue stroma was moderately collagenous with moderate cellularity. Long slender spindle shaped cells and plumb spindle shaped cells were seen arranged in a streaming pattern. Few areas showed irregular arrangement of spindle cells. At the central areas the cellularity was intense with same type of cells. In some areas the spindle cells were arranged in herring bone pattern. Through out the stroma, nucleus was bland and vesicular in nature. Vascularity was moderate with many formed blood vessels in which some of them are engorged. Inflammatory infiltrates were minimal”.

Immunohistochemistry was diffusely strongly positive for SMA and negative for desmin, myogenin and PR. These features were consistent with myofibroma.

Patient was under regular follow up for one year and no recurrence was noted.

## DISCUSSION

Myofibroma is a rare benign spindle cell tumor that consists of myofibroblasts. Since 1981, when a report by Chung and Enzinger<sup>2</sup> appeared, 94 cases of oral myofibromas with well-documented data have been reported in the English-language literature. Tumors have involved the mandible (33%), gingiva (23%),

tongue (15%), cheek or buccal mucosa (12%), palate (8%), lip (4%), and other areas (5%). The lesions can appear at any age (from birth to 70 years), but they occur mainly in children (children, 69%; adults, 31%). There is a slight predilection for male individuals (male-to-female ratio, 1.2:1).<sup>5</sup>

In cases of gingiva, the tumor is larger, but the duration is shorter than the mean value of all lesions. This shows that gingival lesions can grow more rapidly than those in other regions. Myofibroma typically is a painless mass that sometimes exhibits rapid enlargement,<sup>6</sup> and it clinically resembles a malignant process.<sup>7</sup> When the gingiva is affected by the lesion, it presents as a swelling, hence the clinical differential diagnosis includes Pyogenic granuloma, Fibrous epulis and Peripheral odontogenic fibroma.

In general, aggressive tumors are defined on the basis of biologic behavior and histologic type, and they exhibit rapid growth, a large size, tooth displacement, root resorption, and cortical bone thinning or perforation.<sup>8</sup> Following three microscopic features are considered essential to characterize solitary myofibromas:

1. The zonation pattern of cell arrangement.
2. Cell immunoreactivity to smooth actin but not desmin.
3. Absence of cell malignancy.<sup>2</sup>

It has to be differentiated with following tumours derived from myofibroblastically differentiated mesenchymal cells-

1. **Low grade myofibrosarcomas** should be considered first since myofibromas may exhibit transient mild infiltration of peripheral structures and occasional regressive ulceration.<sup>9</sup> However myofibrosarcomas have cells with high mitotic index, abnormal mitoses, and consistent infiltrative features or persistent ulceration, lack the typical zoning pattern and are immunoreactive to both smooth actin and desmin.<sup>10</sup>

2. **Nodular fasciitis** is another myofibroblastic neoplasm but with no zonation, desmin-

positive cells and a strongly myxomatous stroma.<sup>11</sup> The benign and rare oral myofibroblastoma again shows no zonation with cells often immunoreactive to CD-34.<sup>12</sup>

3. **Inflammatory pseudofibroblastic tumour** though exhibiting zonation, shows abundant foci of lympho-plasmocytic cells and dense collagenous bundles, while cells are CD-68 immunoreactive, which does not occur in myofibromatosis.<sup>13</sup>

4. **Leiomyomas** are akin to myofibromas in arising from smooth muscle cells and therefore are immunoreactive for smooth actin, however cells have blunt ended nuclei arranged in dense crossing bundles with no zonation and are desmin-positive.<sup>14</sup>

5. **Neural tumors** including schwannomas are easily recognizable by the typical palisades of spindle cells devoid of actin and rich in S-100 protein.<sup>14</sup>

Histopathologically myofibroma exhibits a biphasic pattern of light and dark-stained areas. The light area mainly consists of spindle cells with eosinophilic cytoplasm and tapering or cigar-shaped nuclei, arranged in short fascicles or whorls and nodules, at the periphery of the lesion. However, sometimes these cells are distributed haphazardly throughout the lesion. In contrast, the more intensely stained areas, located more centrally, consist of round cells or small spindle cells arranged around thin-walled, irregularly branching, hemangiopericytoma-like blood vessels. These cells have basophilic nuclei, small eosinophilic cytoplasm, and indistinct cell margins. In some cases the light and dark areas are not separate and the two cell subpopulations are intermixed.<sup>16</sup> Mitotic figures are only rarely observed but lesions deeply located are often ill-defined and focally tend to infiltrate the surrounding tissue.<sup>17</sup> Immunohistochemically, myofibroma cells express  $\alpha$ -SMA, muscle-specific actin, and vimentin and are negative for desmin, S-100 protein, and CD34.<sup>18</sup>

The cause of myofibroma is presently unknown. Trauma or injury can lead to the development of the lesion. It is believed that

myofibroma is derived from myofibroblast cells. Myofibroblasts cells are related to play a role in wound healing.<sup>19</sup>

Surgical excision is the treatment of choice for myofibroma. The prognosis of this rare tumor is excellent after conservative surgical curettage or resection.<sup>20</sup> According Daimaru et al<sup>21</sup>, the recurrence rate is only 7% after excision.

## CONCLUSION

Oral myofibroma usually appears alarming to the clinician due to its occurrence in very young age rapid growth which may resemble a malignancy. But they are completely benign and prognosis is excellent after complete surgical excision. Traumatic etiology can be attributed to this case.

Differential diagnoses includes benign and malignant spindle cell lesions of nerve tissue or smooth muscle origin, such as neurofibroma, leiomyoma and sarcomas. Thus, knowledge about myofibroma is important to establish the correct diagnosis and to avoid morbidity due to unnecessary aggressive therapy.

## REFERENCES

1. Stout AP. Juvenile fibromatoses. *Cancer* 1954;7:953–78.
2. Chung EB, Enzinger FM. Infantile myofibromatosis. *Cancer*. 1981;48:1807-18.
3. Liu CJ, Chang KW. “Infantile” myofibroma of the oral cavity: Report of case. *J Oral Maxillofac Surg* 2001;59:471-2.
4. Smith KJ, Skelton HG, Barrett TL, Lupton GP, Graham JH. Cutaneous myofibroma. *Modern Pathology* 1989;12(6):603–9.
5. Rubin BP, Bridge JA. Myofibroma/myofibromatosis, in Fletcher CD, Unni KK, Mertens F, (eds). *World Health Organization Classification of Tumours. Pathology and Genetics. Tumours of Soft Tissue and Bone*. Lyon, France: IARC Press, 2002, p 59.
6. Neville BW, Damm DD, Allen CM, et al. Soft tissue tumors, in Neville BW, Damm DD, Allen CM, et al (eds). *Oral and Maxillofacial*

*Pathology* (ed 3). Philadelphia, PA: WB Saunders, 2009, p 515

7. Foss RD, Ellis GL. Myofibromas and myofibromatosis of the oral region: A clinicopathologic analysis of 79 cases. *Oral Surg Oral Med Oral Pathol Oral Radiol Endod* 2000;89:57.
8. Troulis MJ, Williams WB, Kaban LB: Staged protocol for resection, skeletal reconstruction, and oral rehabilitation of children with jaw tumors. *J Oral Maxillofac Surg* 2004;62:335.
9. Scheper MA, DiFabio VF, Sauk JJ, Nikitakis NG. Myofibromatosis: A case report with a unique clinical presentation. *Oral Surg Oral Med Oral Pathol Oral Radiol Endod* 2005;99:325-30.
10. Mentzel T, Dry S, Kalenkamp D, Fletcher CD. Low-grade myofibroblastic sarcoma: Analysis of 18 cases in the spectrum of myofibroblastic tumors. *Am J Surg Pathol* 1998;22:1228-38.
11. Dayan D, Nasrallah V, Vered M. Clinicopathologic correlations of myofibroblastic tumors of the oral cavity: I. no nodular fasciitis. *J Oral Pathol Med* 2005;34:426-35.
12. Montgomery E, Speight PM, Fisher C. Myofibromas presenting in the oral cavity: A series of 9 cases. *Oral Surg Oral Med Oral Pathol Oral Radiol Endod* 2000;89:343-8.
13. Poh CF, Priddy RW, Dahlman DM. Intramandibular inflammatory myofibroblastic tumor – A true neoplasm or reactive lesion? *Oral Surg Oral Med Oral Pathol Oral Radiol Endod* 2005;100:460-6.
14. Jordan RCK, Regezi JA. Oral spindle cell neoplasms: A review of 307 cases. *Oral Surg Oral Med Oral Pathol Oral Radiol Endod* 2003;95:717-24.
15. Foss RD, Ellis GL. Myofibromas and myofibromatosis of the oral region: A clinicopathologic analysis of 79 cases. *Oral Surg Oral Med Oral Pathol Oral Radiol Endod* 2000;89:57-65.
16. “Myofibroma and myofibromatosis,” in Enzinger and Weiss’s *Soft Tissue Tumors*, S. W. Weiss and J. R. Goldblum, Eds., pp. 357–363, Mosby, St Louis, Miss, USA, 2001.

17. Jones AC, Freedman PD, Kerpel SM. Oral myofibromas: a report of 13 cases and review of the literature. *Journal of Oral and Maxillofacial Surgery* 1994;52(8):870-5.
18. Chang JYF, Kessler HP. Masson trichrome stain helps differentiate myofibroma from smooth muscle lesions in the head and neck region. *Journal of the Formosan Medical Association* 2008;107(10):767-73.
19. Darby I, Skalli O, Gabbiani G. Alpha-smooth muscle actin is transiently expressed by myofibroblasts during experimental wound healing. *Lab Invest* 1990;63(1):21-9.
20. Sugatani T, Inui M, Tagawa T, Seki Y, Mori A, Yoneda J. Myofibroma of the mandible. Clinicopathologic study and review of the literature. *Oral Surg Oral Med Oral Pathol Oral Radiol Endod* 1995;80:302-9.
21. Daimaru Y, Hashimoto H, Enjoji M. Myofibromatosis in adults (adult counterpart of infantile myofibromatosis). *Am J Surg Pathol* 1989;13:859-65.

**How to cite this article:** Sobhana CR, Suresh B, Rawat SK, Yadav S. Aggressive Myofibroma of Gingiva: A Case Report. *Arch of Dent and Med Res* 2016;2(2):56-60.